

Hemichorea-Hemiballism after Acute Ischemic Stroke

Benjamin Wagner, MD*, Peter Fuhr, MD and Gian Marco De Marchis, MD, MSc

Neurology Department, University Hospital of Basel, Switzerland

*Corresponding author: Benjamin Wagner, Neurology Department, University Hospital of Basel, Petersgraben 4, 4031 Basel, Switzerland, E-mail: benjamin.wagner@usb.ch

Received: 📅 July 19, 2019; Accepted: 📅 August 07, 2019; Published: 📅 August 09, 2019

Abstract

Movement disorders can be part of acute stroke onset which is important to recognize. We report a rare presentation of a 89-year-old woman who developed hemichorea-hemiballism after an acute stroke caused by an ischemic lesion in the head of the left caudate nucleus; a video segment is included. However, lesions in different parts of the motor pathways have been reported, which led to the hypothesis that the pathology in movement disorders results from a dysfunction in motor network connectivity, with the putamen as central control point within the basal ganglia-thalamo-cortical motor loop. Despite of the tendency to resolve, treatment may be required for symptom control.

Keywords: Chorea, Motor network, Movement disorders, Stroke, Hemiballism

Introduction

Movement disorders are a rare symptom of an acute ischemic stroke. A wide range of movement disorders can result, which include chorea, ballism, athetosis, dystonia, tremor, myoclonus, stereotypies, and akathisia. Hemichorea, with or without hemiballism, is with 36-38% the most frequent post-stroke movement disorder, followed by dystonia [1,2].

Hemichorea is a hyperkinetic disorder on one body-side characterized by jerky, nonrhythmic, rapid, not suppressible movements that shift from muscle to muscle. Hemiballism consists of unilateral, nonrhythmic, rapid, high-amplitude movements of the proximal limbs. Here we report on a woman who developed hemichorea-hemiballism after an acute ischemic stroke; a video is included.

Case Report

An 89-year-old woman presented with a 2-day history of in-

voluntary movements of the right arm and leg with acute onset. She had a history of atrial fibrillation, and was therefore taking apixaban. There were no other comorbidities. The clinical exam revealed hemichorea-hemiballism of the right arm and leg (Video 1, segment 1). Vitals and laboratory assessment revealed no abnormality, she was conscious and oriented. Cerebral Magnetic Resonance Imaging showed an acute ischemic lesion in the head of the left caudate nucleus (Figure 1). We maintained apixaban and started atorvastatin for recurrence prophylaxis. Symptomatic treatment consisted in risperidone 2 mg over five days upon admission. Hemichorea-hemiballism gradually abated (Video 1, segment 2), and did not reappear after stopping risperidone.

Discussion

The exact prevalence of movement disorders after an acute stroke is unknown, partly because of their rarity. Retrospective studies and case reports suggest a prevalence around 1-4% [3], and an estimated incidence of 0.08% per year [2].

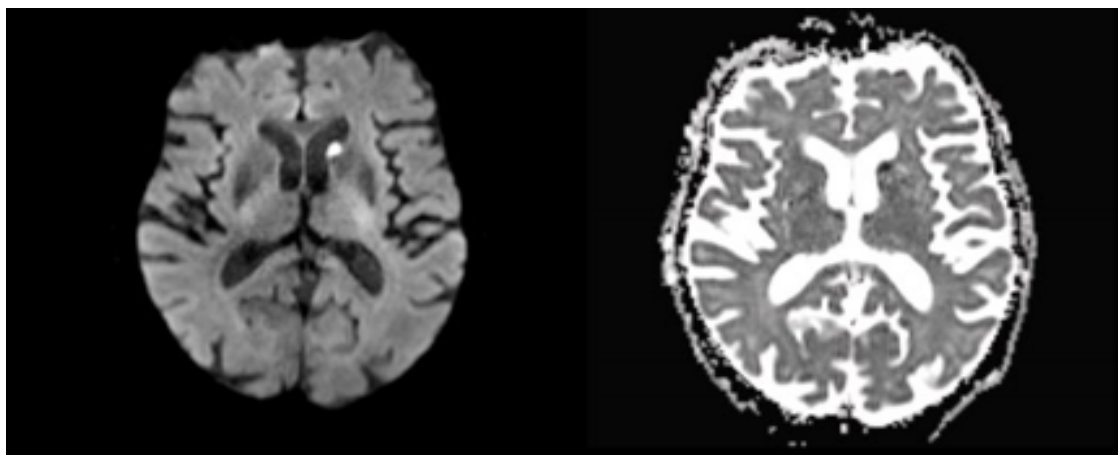


Figure 1: Diffusion-weighted MRI showed a lacunar ischemic lesion in the head of the left caudate nucleus (left side). Apparent Diffusion Coefficient showed a corresponding diffusion restriction (right side).

Mostly, the movement disorder occurs at the onset of acute stroke but a delay by days or months is also described [3]. Most of these spontaneously resolve [2], but treatment is recommended to reduce burden and distress. Hemichorea and hemiballism share similar pathophysiology and can be treated with anti-dopaminergic therapy. To minimize the risk of drug-induced parkinsonism and tardive dyskinesia, anti-dopaminergic therapy should be promptly stopped after hemichorea and hemiballism abate.

The culprit lesion is typically located in the contralateral caudate nucleus (hemichorea) and subthalamic nucleus (hemiballism). However, other lesion locations have been reported, such as the lentiform nucleus, thalamus or cortex [2-4]. These findings led to the hypothesis that the pathology in movement disorders results from a dysfunction in motor network connectivity [3,4].

A recent study, realized with a validated technique called lesion network mapping, found that strokes causing hemichorea-hemiballism are located within a single network of functional connectivity to the posterolateral putamen, with a broad anatomical heterogeneity of the lesions [5]. These findings indicate the putamen as central control point within the basal ganglia-thalamo-cortical motor loop. Furthermore, causes of non-ischemic hemichorea-hemiballism support a putaminal dysfunction, like non-ketotic hyperglycemia or Huntington disease.

Conclusion

An acute onset of movement disorders can be due to an acute ischemic stroke, especially when one-sided. The lesions can occur at different parts in the motor circuit. This heterogeneity raises the possibility of individual brain plasticity within the motor network connectivity. In our case of hemichorea-hemiballism, the acute ischemic lesion was diagnosed in the head of the left caudate nucleus. Most of movement disorders due to an acute stroke subside over time and require only temporary symptomatic treatment.

Funding Sources and Conflicts of Interest

The authors report no sources of funding and conflicts of interest.

Author Contributions

Benjamin Wagner: made the video and wrote the manuscript; Gian Marco De Marchis: critical revision of manuscript; Peter Fuhr: critical revision of manuscript.

Author Disclosures

Benjamin Wagner reports no disclosures.

Gian Marco De Marchis is or was supported by the following grants:

Swiss National Science Foundation (PBBEP3_139388); Science Funds [Wissenschaftsfonds] of the University Hospital Basel and University of Basel; Bangerter-Rhyner-Stiftung; Swisslife Jubiläumsstiftung for Medical Research; Swiss Neurological Society; Fondazione Dr. Ettore Balli; Travel honoraria by Bayer; speaker honoraria by Medtronic and BMS/Pfizer.

Peter Fuhr is or was supported by Swiss National Science Foundation, Swiss Multiple Sclerosis Society, Synapsis Foundation, Parkinson Schweiz, Novartis Research Foundation, Gossweiler Foundation, Freiwillige Akademische Gesellschaft Basel, Mach-Gaensslen-Stiftung, Botnar Foundation, Bangerter Foundation, and by unconditional research grants from industry (Roche, AbbVie, Biogen, General Electrics).

Ethical Compliance Statement

The authors confirm that the approval of an institutional review board was not required for this work. We confirm that we have read the Journal's position on issues involved in ethical publication and affirm that this work is consistent with those guidelines.

Authors` has received patient consent form for publication of the [Video 1](#).

References

1. Alarcón F, Zijlmans JC, Dueñas G, Cevallos N (2004) Post-stroke movement disorders: Report of 56 patients. *J Neurol Neurosurg Psychiatry* 75: 1568-1574.
2. Ghika-Schmid F, Ghika J, Regli F, Bogousslavsky J (1997) Hyperkinetic movement disorders during and after acute stroke: The Lausanne Stroke Registry. *J Neurol Sci* 146: 109-116.
3. Mehanna R, Jankovic J (2013) Movement disorders in cerebrovascular disease. *Lancet Neurol* 12: 597-608.
4. Chung SJ, Im JH, Lee MC, Kim JS (2004) Hemichorea after stroke: Clinical-radiological correlation. *J Neurol* 251: 725-729.
5. Laganieri S, Boes AD, Fox MD (2016) Network localization of hemichorea-hemiballismus. *Neurology* 86: 2187-2195.

Open Access Declaration

This article is distributed under the terms of the Creative Commons Attribution 4.0 International License (<http://creativecommons.org/licenses/by/4.0/>), which permits unrestricted use, distribution, and reproduction in any medium, provided you give appropriate credit to the original author(s) and the source of content.